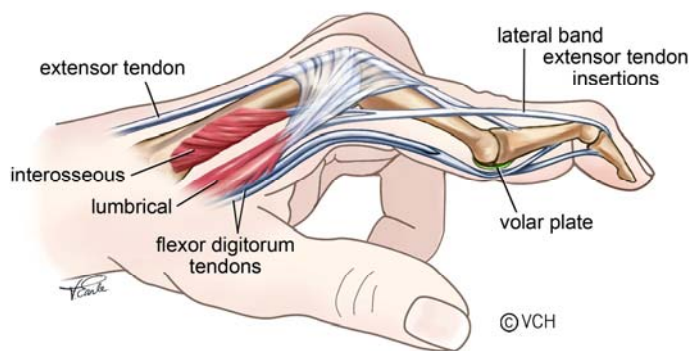


## Best Practice Recommendations for Management of Swan Neck Deformity in Rheumatoid Arthritis

### DESCRIPTION

The Swan Neck deformity (SND) is characterized by metacarpophalangeal (MCP) joint flexion, proximal interphalangeal joint (PIP) hyperextension and distal interphalangeal joint (DIP) flexion.



### Sites of Onset <sup>1</sup>

#### MCP Joint

Chronic synovitis of the MCP joint causes reflex muscle spasm of the intrinsic muscles, leading to muscle contracture and flexion of the MCP and hyperextension of the PIP. This is the most frequent cause of SND in adult Rheumatoid Arthritis (RA).

#### PIP Joint

Chronic synovitis of the PIP joint leads to stretching of the volar plate and the transverse retinacular ligament, allowing dorsal migration of the lateral bands and hyperextension of PIP joint. It also causes attenuation or possible rupture of flexor digitorum superficialis (FDS), which destabilizes the PIP joint. PIP hyperextension, in turn, creates tension on the flexor digitorum profundus (FDP) causing flexion of the DIP. This is the least common cause of SND in adult RA because synovitis of the PIP joint most frequently results in a Boutonniere deformity.

## DIP Joint

Chronic synovitis causes stretching and rupture of the extensor tendon at the DIP joint pulling it into flexion and the PIP joint into hyperextension. It is the most common cause of SND in Juvenile Idiopathic Arthritis (JIA) and Psoriatic Arthritis (PsA).

## Classification

### Types of Deformity – Nalebuff: <sup>2</sup>

- I No limitation of PIP joint motion in all positions
- II Limitation of PIP joint in certain positions (MCP joint extension and radial deviation)
- III Limitation of PIP joint in all positions of MCP joint (no radiological joint changes)
- IV Stiff PIP joint with radiological changes

## ASSESSMENT

### Inflammation <sup>3,4</sup>

#### MCP Joint

- Feel for heat using dorsum of hand over joint surface.
- Observe for swelling\* around joint.
- Palpate for effusion\*. While supporting the MCP joint in 45° of flexion, place thumbs on either side of the joint and alternately apply medial & lateral pressure. Feel for fluid fluctuation.
- If negative, palpate for tenderness by applying medial and lateral pressure to the joint line.
- If negative, check for stress pain by applying overpressure at the end of range in extension, while supporting the proximal phalange.

#### PIP Joint

- Feel for heat using dorsum of hand over joint.
- Observe for swelling\* around joint.
- Palpate for effusion\* by grasping PIP joint on its dorsal and volar surfaces using your thumb and index finger. With your other hand, grasp the medial and lateral surfaces of the joint. Apply pressure to the anterior and posterior surfaces and feel for fluid fluctuation medio-laterally.
- If negative, palpate for tenderness by applying medial and lateral pressure to the joint line.

- If negative, check for stress pain by applying overpressure at end of range in flexion and extension, while supporting the proximal phalange.
- To assess the circumference of the affected joint, use a tape measure or an Arthrocircameter if available.

## DIP Joint

- Feel for heat using dorsum of hand over joint.
- Observe for swelling\* around joint.
- Palpate for effusion\*. Using your thumb and index finger, grasp the DIP joint on its dorsal and volar surfaces. With your other hand, palpate the medial and lateral surfaces of the joint. Apply pressure to the anterior and posterior surfaces and feel for fluid fluctuation medio-laterally.
- If negative, palpate for tenderness by applying medial and lateral pressure to the joint line.
- If negative, check for stress pain by applying overpressure at end of range in flexion and extension while supporting the middle phalange.
- To assess the circumference of the affected joint, use a tape measure or an Arthrocircameter if available.

\*An **effusion** is the accumulation of synovial fluid within the joint capsule, while **swelling** refers to the build up of fluid both within the joint and in the soft tissue surrounding it.

## Range of Motion <sup>5</sup>

### MCP Joint

Flexion / Extension: Place goniometer on dorsal surface of joint. If joint is swollen or deformed, place it on the lateral aspect of index and medial aspect of little finger.

### PIP / DIP Joints

Flexion / Extension: Place goniometer on dorsal surface of joint. If joint is swollen or deformed, place it on lateral aspect of joint. Document deformity by tracing a lateral view of finger or taking a photograph.

## Joint and Ligament Tests

### MCP Joint

Collateral Ligaments: MCP joint must be flexed to 90° to ensure the collateral ligaments are taut. Grasp the proximal phalange and gently apply pressure to radial and then to ulnar side of phalange. If normal, no movement occurs.<sup>6,7</sup>

Palmar Subluxation: With MCP joint in neutral, palpate along dorsal surface of proximal phalange from distal to proximal. If subluxation is present there will be a palpable “step” at the joint line.

## **PIP Joint**

PIP Joint Hyperextension: If hyperextension is present, the volar plate, FDS tendon and the joint capsule may be stretched. PIP joint may normally hyperextend, so compare to other hand.

Lateral Bands: If the lateral bands slip dorsally during active flexion, there is a notable “snap”.

## **Special Tests**

### **MCP Joint**

Test for Extensor Lag of Extensor Communis (EC): With wrist supported in neutral, ask patient to actively extend MCP joints with IP joints flexed. Extension to at least neutral should occur.<sup>8</sup>

Test for Intrinsic Tightness and PIP Capsular Tightness (Bunnel-Littler): Hold MCP joint in maximum extension and passively flex PIP joint, stretching the intrinsics. Next, place MCP joint in flexion (relaxing the intrinsics), passively flex the PIP joint and note the difference in PIP range. If range increases when the MCP is flexed, the intrinsics are tight. If PIP cannot be fully flexed limitation is likely due to PIP joint capsular tightness. Repeat test for each finger. Test is not valid if MCP is subluxed or a fixed Swan Neck deformity (SND) exists.<sup>9,10,11</sup>

Test for Lumbrical Tightness: Ask the patient to make a composite (full fist). If there is paradoxical DIPJ extension with full MCPJ flexion, this is considered a positive test for lumbrical tightness.<sup>18</sup>

### **PIP Joint**

Test for Rupture of FDS: In later stages, test for tendon rupture by holding the adjacent fingers in full extension (at MCP and IP joints) while asking patient to flex the finger being tested. If the FDS is functioning normally, the PIP joint will flex while the DIP joint remains in extension.<sup>8,9</sup>

## DIP Joint

Test for EC Tendon Function: Stabilize PIP joint in extension and ask patient to actively extend DIP joint. If not able, this indicates a stretched or ruptured terminal tendon of the EC.

## Skin Condition

Check for skin breakdown across volar and dorsal aspects of the finger.

## Hand Function

Fist: Ask patient to make a fist. If impaired, record distance from fingertips to proximal palmar crease,<sup>11</sup> or record a % of full fist.

Tuck: Measure distance from fingertips to palmar digital crease, at base of fingers,<sup>8</sup> or record % of full tuck.

Pinch Strength: Use a pinch gauge to measure strength of a tripod pinch. The patient should be comfortably seated and positioned with shoulder adducted and in neutral rotation, elbow flexed to 90°, forearm in mid rotation and wrist in 15-30° extension. Repeat 3 times and average scores.<sup>11,13</sup>

Grip Strength: An adapted sphygmomanometer is easier to use, though less reliable than JAMAR, for the hand with arthritis. A Vigorometer can also be used. The test position is the same as above. Repeat 3 times and average scores.<sup>11,13</sup>

Opposition: Ask patient to make a circle, using tip of thumb to each fingertip. Note shape of circle (round or oval). If unable to reach fingertip, note location on finger where patient can oppose or use a ruler to measure the distance from fingertip to tip of thumb.<sup>14</sup>

Dexterity: Ask patient if they have difficulty: writing; doing up buttons or small fasteners; and picking up coins from a table and holding them in palm. Standardized tests are available in Dexterity section of Arthritis Hand Function Test (AHFT)<sup>14</sup> or Section II of the Michigan Hand Outcomes Questionnaire.<sup>24</sup>

## TREATMENT

### Modalities

- Ice to decrease swelling and pain<sup>20</sup>
- Contrast baths to decrease swelling
- Moist heat applied with finger positioned at end of available range to increase range<sup>20</sup>

- Laser to decrease pain <sup>15,25</sup>
- Ultrasound in water to decrease joint tenderness <sup>15,25</sup>
- Transcutaneous Nerve Stimulation (TNS) to decrease pain <sup>15,25</sup>
- Wax followed by hand exercises <sup>15,25</sup>

## Exercise

- Acute joint inflammation can cause reduced tensile strength of tissue. Therefore, stretching exercises should be avoided while joint is inflamed because of risk of overstretching and tearing tissue.<sup>26,27</sup>
- Active and passive ROM for MCP, PIP, DIP joints.<sup>16</sup>
- Active ROM of DIP joint while stabilizing PIP joint in slight flexion.
- Active flexion of PIP joint while stabilizing MCP joint in neutral.
- Tendon Gliding: Start with fingers straight. (1) Flex the MCP joints keeping PIP & DIP joints straight, to form a “tabletop”. Return to start position. (2) Flex PIP & DIP joints, keeping MCP joints straight to form a “tuck”. Return to start position. (3) Flex PIP & MCP joints while keeping DIP joints straight, to form a “straight fist”. (4) Flex MCP, PIP, & DIP joints to form a full “fist”.<sup>17</sup>
- Intrinsic Stretch: Lumbricals: To actively stretch the lumbricals, ask patient to actively flex DIP and PIP joints with MCP joints in extension.<sup>18</sup> Hold stretch for 10 - 30 seconds ~ 2 – 5 minutes<sup>33</sup>, 3 - 4 reps, 2 - 3 times per week or daily if possible.<sup>26</sup> To passively stretch the interossei, hold the MCP joint in hyperextension and passively flex the PIP & DIP joints as much as possible. Repeat for each finger.<sup>18</sup> In the presence of PIP joint synovitis, reduce force on PIP joint and duration of stretch. Hold stretch for 10 – 30 seconds ~ 2 – 5 minutes<sup>33</sup>, 3 - 4 reps, 2 – 3 times per week or daily if possible.<sup>26</sup>

## Splinting

### Purpose:

Anti-swan neck splints (ASNS) are designed to correct or reduce swan neck deformity and improve hand function by permitting full PIP joint flexion and preventing hyperextension.<sup>23</sup>

### Indications:

- Type I & II: When the PIP joint is correctible to 0°, use an ASNS to position the PIP joint in flexion, blocking the last 10° of extension, in order to prevent tightening of the intrinsic muscles and other soft tissues.<sup>28,30,31</sup>

- Type III: When the PIP joint is not correctible to 0°, an ASNS can be used to decrease hyperextension of joint, enabling the finger to flex within its available range of movement to improve function.

## Splint Options

### Day Use

- Low temperature thermoplastic ASNS (recommended material: 1.6mm Redifit): They are an inexpensive option, so are useful to “trial” before recommending a silver ASNS. The width of the proximal and distal bands can be increased to reduce pressure on skin.
- Silver ASNS (Cygnet Silver Ring Co., Silver Ring Co., Digit Splint Co.): <sup>12 19,29</sup> Although an expensive option, they are cosmetically acceptable and hygienic. They can be made with anti-deviation bars to reduce medial/lateral instability and one style (Cygnet) can be adjusted for changes in swelling. They can be made from wide gauge silver or fitted with a volar plate to disperse pressure.
- Oval 8 ASNS: They are inexpensive, lightweight and discrete, most useful in the early stage of the deformity because they may not be rigid enough to control marked hyperextension. As the splint is fabricated in 0° of extension, they need to be heat adjusted to position PIP joint in approximately 10° of flexion.<sup>13, 29</sup>

### Night Use

- Gutter Finger splint: To position PIP joint out of hyperextension when only one or two digits per hand are involved, and there is no MCP involvement.
- Hand Resting splint: (see OTIIA-7) To position PIP joint out of hyperextension, when multiple PIP joints are involved, and/or there is involvement of the MCP joints and the wrist.
- MCP Protection splint (see OTIIA-9) If MCP joint is the initial site of synovitis, a MCP protection splint can be used to rest inflamed MCP joints and guide hand use with the intrinsic muscles in their lengthened position.<sup>21, 22,32</sup>

## Wearing Regime

- ASNS: Start by wearing ASNS for one hour, check skin for pressure areas and increase to full day as tolerated. These splints are not recommended for overnight wear, instead use one of the “night use “options.

- Gutter Finger splint: Start by splint wearing for one hour, check skin for pressure areas and increase to full night as tolerated.
- Hand Resting splint: Start by splint wearing for one hour, check skin for pressure areas and increase to full night as tolerated. (see OTIID-2)
- MCP Protection: Start by splint wearing for one hour, check skin for pressure areas and increase as tolerated. (see OTIIA-9)

## Precautions

- Skin breakdown <sup>31</sup>
- Fit of splint may change as swelling fluctuates <sup>29</sup>
- May cause increased pain if joint is inflamed <sup>31</sup>
- May splay the fingers, promoting ulnar drift (low temp thermoplastic style)
- ASNS are easy to lose <sup>29</sup>
- Splints need to be monitored by patient to ensure proper position is maintained and adjusted as needed.

## Contraindications

- Nodules near PIP joint can interfere with fit
- A fixed ASN deformity

## Joint Protection

- If intrinsic muscles are tight, avoid hand activities that require an “intrinsic plus” position (i.e. holding a book) and choose alternate methods that encourage a flat hand or MCP extension. <sup>18, 23, 28</sup>
- Use assistive devices with padded, enlarged handles if grip is restricted.

Note: These recommendations are based on materials ranging from systematic reviews, published studies, expert opinion, reviews of clinical texts and the expertise of the physiotherapists and occupational therapists at the Mary Pack Arthritis Program.

## REFERENCES

1. Melvin JL. Rheumatic Disease in the Adult and Child: Occupational Therapy and Rehabilitation. 3<sup>rd</sup>ed. F.A. Davis Co:1989;284-287.
2. Ruby LK (editor). Hand Clinics- Rheumatoid Arthritis of the Hand and Wrist 1996;12:534-536.
3. Klinkhoff, A. et al. An Experiment in Reducing Interobserver Variability of the Examination for Joint Tenderness. Journal of Rheumatology 1988;15:492-494.
4. Bombardier C et al. Illustrated Guide to a Standard Examination for Joint Tenderness and Swelling. 1987
5. Groth G et al. Goniometry of the Proximal and Distal Interphalangeal Joints. Journal of Hand Therapy - Part 1. 2001: 18-22.
6. Magee DJ. Orthopedic Physical Assessment. 4<sup>th</sup> ed. Saunders: 2002;392-393.
7. Bielefeld T et al. The Unstable Metacarpophalangeal Joint in Rheumatoid Arthritis: Anatomy, Pathomechanics, and Physical Rehabilitation Considerations. Journal of Orthopaedic and Sports Physical Therapy 2005;35-8:502-520.
8. Mackin EJ, Callahan AD, Skirven TM et al (editors). Rehabilitation of the Hand and Upper Extremity. 5th ed. Mosby: 2002;123-127.
9. Hoppenfeld S. Physical Examination of the Spine and Extremities. Prentice-Hall:1976;101-2.
10. Mackin EJ, Callahan AD, Skirven TM et al (editors). Rehabilitation of the Hand and Upper Extremity. 5th ed. Mosby: 2002;132-33
11. Melvin JL. Rheumatic Disease in the Adult and Child: Occupational Therapy and Rehabilitation. 3<sup>rd</sup>ed. F.A. Davis Co:1989;347-353.
12. Melvin JL. Rheumatic Disease in the Adult and Child: Occupational Therapy and Rehabilitation. 3<sup>rd</sup>ed. F.A. Davis Co:1989;414-416.
13. Mackin EJ, Callahan AD, Skirven TM et al (editors). Rehabilitation of the Hand and Upper Extremity. 5th ed. Mosby: 2002;1573-76.
14. Backman C. et al. Arthritis Hand Function Test: Development of a standardized assessment tool. Occupational Therapy Journal of Research 1991;11-4:245-256.
15. Ottawa Panel Evidence-Based Clinical Practice Guidelines for Electrotherapy and Thermotherapy Interventions in the Management of Rheumatoid Arthritis in Adults. Physical Therapy 2004;84-1;1016-1043.
16. O'Brien AV, Jones P, Mullis R et al. Conservative Hand Therapy Treatments in Rheumatoid Arthritis - A Randomized Controlled Trial. Rheumatology 2006;45:577-583.
17. Wehbe M. Tendon Guiding Exercises. AJOT 1987;41-3:164-167.
18. Harrell P. Biomechanics of the Hand. ARHP Audioconference:June 16, 2005.
19. ter Schegget, M et al. A study Comparing Use and Effects of Custom-made versus Prefabricated Splints for Swan Neck Deformity in Patients with Rheumatoid Arthritis. Br J Hand Ther. 2002;5-4:101-107.
20. Mackin EJ, Callahan AD, Skirven TM et al (editors). Rehabilitation of the Hand and Upper Extremity. 5th ed. Mosby: 2002;1748-1750.
21. MPAP OT Document. MCP Protection Splint for RA Hand – Construction. OTIIA-8.
22. MPAP OT Document. MCP Protection Splint Protocol. OTIIA - 9
23. Mackin EJ, Callahan AD, Skirven TM et al (editors). Rehabilitation of the Hand and Upper Extremity. 5th ed. Mosby: 2002;1575 - 1580.

s

24. Chung KC et al. Reliability and Validity Testing of the Michigan Hand Outcome Questionnaire. *Journal of Hand Surgery* 199;23A:575-587
  25. Cochrane Musculoskeletal group Cochrane Database of Systematic Reviews 1, 2006: Robinson et al. Thermotherapy for treating rheumatoid arthritis Robinson et al.; Brousseau L et al. Transcutaneous electrical nerve stimulation for the treatment of rheumatoid arthritis in the hand; Casimiro et al. Therapeutic ultrasound for the treatment of rheumatoid arthritis; Brousseau L et al. Low-level laser (class 1,11,111) for treating rheumatoid arthritis.
  26. *Clinical Care in the Rheumatic Diseases* (3<sup>rd</sup> edition). ARHP 2006;212-15.
  27. Myths and Truths of Stretching. *Orthopedic Division Review*. Jan/Feb 2001
  28. Biese J. Therapist's Evaluation and Conservative Management of Rheumatoid Arthritis in the Hand and Wrist. 5<sup>th</sup> ed. Missouri: Mosby 2002;1569-1582
  29. Van Der Giesen FJ, Van Lankveld WJ, Kremers-Selten C et al. Effectiveness of Two Finger Splints for Swan Neck Deformity in Patients with Rheumatoid Arthritis. A Randomized, Crossover Trial. *Arthritis & Rheum* 2009;61:1025-1031
  30. Spicka C, Macleod C, Adams j, Metcalf C. Effect of silver ring splints on hand dexterity and grip strength in patients with rheumatoid arthritis: an observational pilot study. *Hand Therapy* 2009;14:53-5731.
  31. Zijlstra T, Heijnsdijk-Rouwenhorst L, Rasker J. Silver ring splints improve dexterity in patients with rheumatoid arthritis. *Arthritis & Rheumatism* 2004;51:947-951
  32. Formsa S, van der Sluis C, Dijkstra P. Effectiveness of a MP – blocking splint and therapy in rheumatoid arthritis: a descriptive pilot study. *Journal of Hand Therapy* 2008;21:347-353
  33. Hoens A. Evidence-Informed Practice for Range of Motion, Stretching and Prolonged Positioning. Providence Health Care – Physiotherapy Services 2011.
-