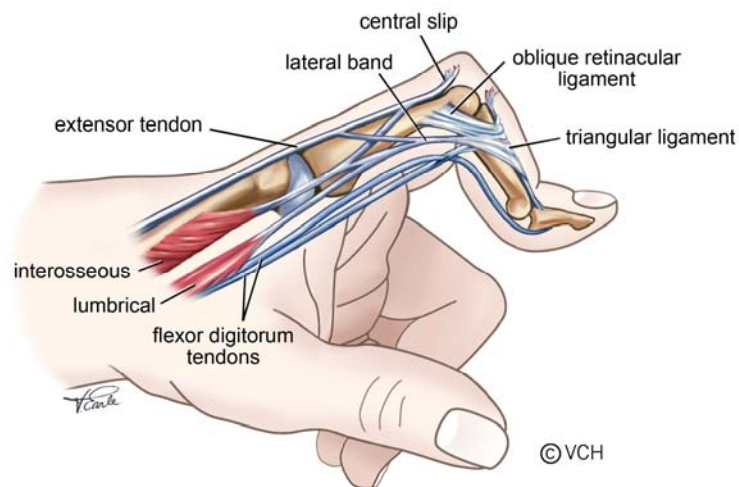


Best Practice Recommendations for Management of Boutonniere Deformity in Rheumatoid Arthritis

DESCRIPTION

The Boutonniere deformity is characterized by proximal interphalangeal (PIP) joint flexion, distal interphalangeal (DIP) joint hyperextension and may include metacarpal phalangeal (MCP) joint hyperextension.



Site of Onset

Chronic synovitis of the PIP joint stretches the dorsal joint capsule and damages the extensor mechanism, weakening its attachment to the joint. The central slip attenuates and cannot maintain full extension. An extension lag develops and the central slip may eventually rupture. The lateral bands of the extensor mechanism displace volarly and become fixed, changing their action to PIP joint flexors by limiting the action of the lumbricals and interossei. The mechanical advantage of the extensor mechanism increases and it hyperextends the DIP joint.²⁰

Classification

Stages of Deformity - Nalebuff: ¹

- I. Mild - PIP joint synovitis with extension lag (10-15°), with or without DIP hyperextension and normal MCP joint.
- II. Moderate - PIP joint flexion (30-40°) with a loss of active extension, DIP hyperextension, with or without MCP hyperextension.

III. Severe - Fixed flexion of PIP, DIP hyperextension, with or without intra-articular erosions and MCP hyperextension.

ASSESSMENT

Inflammation of PIP Joint ^{2, 3}

- Feel for heat using dorsum of hand over joint.
- Observe for swelling* around joint.
- Palpate for effusion* by grasping PIP joint on dorsal and volar surfaces using your thumb and index finger, with your other hand grasp the medial and lateral surfaces of the joint. Apply AP pressure and feel for fluid fluctuation medio-laterally.
- If negative, palpate for tenderness by applying medial and lateral pressure over the joint line.
- If negative, check for stress pain by applying overpressure at the end of range in flexion and extension, while supporting the PIP joint proximally.
- To measure the circumference of the joint use a tape measure or an Arthrocircameter if available

*An effusion is an accumulation of synovial fluid within the joint capsule, while swelling refers to a build up of fluid both within the joint and in the soft tissue surrounding it.

Range of Motion ⁴

MCP Joint

Flexion / Extension: Place goniometer on dorsal surface of joint. If joint is swollen or deformed, place it on lateral aspect of index and medial aspect of little finger.

PIP / DIP Joints

Flexion / Extension: Place goniometer on dorsal surface of joint. If joint is swollen or deformed, place it on lateral aspect. Document deformity by tracing lateral view of finger or taking a photograph.

Muscle Test ⁵

Flexor Digitorum Profundus (FDP): Stabilize the MCP and PIP joints in extension and ask the patient to flex the DIP joint.

Special Tests

Elson's Test: PIP joint is placed at 90⁰ of flexion over the edge of a table and stabilized by the examiner. Patient attempts to actively extend the PIP joint. If central slip is intact, the DIP joint remains flexed. If central slip is torn, the DIP

joint extends.²⁴

Central Slip Tenodesis Test: With wrist in flexion, place your finger on dorsum of proximal phalange and gently flex MCP joint. If the central slip is intact the PIP joint passively extends. If central slip is torn, the PIP joint remains in flexion.⁶

Test for Oblique Retinacular Ligament (ORL): Stabilize the PIP joint in extension. Then passively flex the DIP and note resistance. Next flex the PIP joint and note resistance to passive DIP flexion. If there is greater range of motion when PIP is flexed, the ORL is tight. If there is equal loss of flexion when PIP is flexed or extended, there may be DIP joint contracture.^{5,7}

Skin Condition

Check for skin breakdown across palmar and dorsal aspects of the finger.

Hand Function

Fist: Ask patient to make a fist. If impaired, measure distance from fingertips to proximal palmar crease,⁸ or record % of full fist.

Tuck: Measure the distance from fingertips to palmar digital crease, at base of fingers, or record % of full tuck.

Pinch Strength: Using a pinch gauge, measure strength of a “tripod “ pinch. The patient should be comfortably seated. Position shoulder in adduction and neutral rotation, elbow at 90° flexion, forearm in mid-rotation and wrist in 15° - 30° extension. Repeat 3 times and average scores.^{8, 10}

Grip Strength: An adapted sphygmomanometer is easier to use, though less reliable than JAMAR, for the hand with arthritis.^{14, 15} A Vigorometer can also be used. The test position is the same as above. Repeat 3 times and average scores.^{8, 10}

Dexterity: Ask patient if they have difficulty writing, doing up buttons or small fasteners, and picking up coins from a table and holding them in palm. Standardized tests are available in Dexterity section of Arthritis Hand Function Test (AHFT)⁹ or Section II of Michigan Hand Outcomes Questionnaire.¹⁸

TREATMENT

Modalities

- Ice to decrease swelling and pain ¹⁹
- Contrast baths to decrease swelling
- Moist heat applied with hand positioned at end of available range to increase range ¹⁹
- Laser to decrease pain ^{11,21}
- Ultrasound in water to decrease joint tenderness ^{11,21}
- Transcutaneous Nerve Stimulation (TNS) to decrease pain ^{11,21}
- Wax followed by hand exercises ^{11,21}

Exercise

- Acute inflammation of joint can cause reduced tensile strength of tissue; therefore, stretching exercises should be avoided while the joint is inflamed because of risk of overstretching and tearing tissue. ^{22, 23} Use caution when applying a stretch, patient should feel tension but not pain.
- Active and passive ROM to MCP, PIP and DIP joints ¹²
- Tendon Gliding: Start with fingers straight. (1) Flex the MCP joints keeping PIP & DIP joints straight, to form a “tabletop”. Return to start position. (2) Flex PIP & DIP joints, keeping MCP joints straight to form a “tuck”. Return to start position. (3) Flex PIP & MCP joints while keeping DIP joints straight, to form a “straight fist”. (4) Flex MCP, PIP, & DIP joints to form a full “fist”.¹³
- Passively stretch ORL by asking patient to hold PIP joint in extension and passively flex the DIP joint.^{14,15} Hold stretch for 10 - 30 seconds ~ 2 – 5 minutes²⁶, 3 - 4 reps, 2 - 3 times per week or daily if possible.²²
- Active DIP joint flexion with PIP joint stabilized in full extension.¹⁵

Splinting

Purpose:

Anti-boutonniere splints are designed to reduce a flexion deformity of the PIP joint and preserve the length of the ORL.

Indications:

- Stage I & II: In the presence of a correctible or partially correctible PIP joint flexion deformity (FD) of less than 40°, use a static extension splint to

maintain PIP joint extension keeping the DIP joint free. Splint should allow active and passive DIP joint range of motion to prevent tightness of the ORL and DIP joint hyperextension.²⁵

- Stage III: If the FD is greater than 40° but partially correctible with a soft end field, a static extension splint may be useful. However, in the presence of a fixed PIP joint FD, with DIP joint & MCP joint hyperextension, splinting is not appropriate.

Splint Options:

Day Use:

- Reverse ASNS: (Cygnet Silver Ring Co., Silver Ring Co., Digi-Splint Co). Although an expensive option, it is cosmetically acceptable and hygienic. It holds the finger in its corrected position and can be adjusted as extension increases. May not be suitable for an enlarged PIP joint. Used in Stage I & II (FD < 40°).
- Anti-boutonniere splint: (Cygnet Silver Ring Co., Digi-Splint Co.) Same as above. More comfortable to wear on an enlarged PIP joint. Used in Stage I & II (FD < 40°).
- Three-point Splint with Strap: (low temperature thermoplastic). An inexpensive option, however it can be bulky, and may splay fingers. It holds the PIP joint in its extended position and is adjusted to improve extension by increasing tension on strap. Used in Stage I, II & III provided the end field of range in extension is soft.
- PIP extension splint (Belly splint): (low temperature thermoplastic) It is a gutter splint with a strap over the dorsum of the PIP joint and a "space" volar to the joint, to promote maximal PIP joint extension. The DIP joint is not incorporated in the splint.¹⁶ It is bulky but inexpensive. Used in Stage I, II & III provided that the end field of range in extension is soft.
- Gutter splint: (low temperature thermoplastic). It positions PIP joint in maximal extension and provides support to joint. A dorsal component may be used in conjunction with the palmar splint to maximize full PIP joint extension.¹⁵ It is useful if joint is inflamed. Inexpensive, but bulky.
- Digisleeve or Coban wrap: Compression can be used to reduce PIP joint swelling. Coban should be applied, wrapping digit from distal to proximal.

Night Use:

- Dorsal Extension Block Splint: (PIP joint extension, DIP joint slight flexion) This splint limits daily activities but is useful for nighttime use.¹⁰
- Gutter splint: See above
- Digi-sleeve or Coban wrap: See above
- Hand Resting splint: (see OTIIA-7) To position PIP joint in extension, when multiple PIP joints are involved, and / or there is involvement of the MCP joints and the wrist.

Wearing regime:

Day Options:

- Initially, wear splint for 30 minutes and check skin for redness. Gradually increase wearing time to all day, or as much as tolerated.
- Remove splint every 3 – 4 hours for ROM and skin check.
- During the day, stretch ORL by passively flexing DIP joint while PIP joint is stabilized in extension. See Exercise section above for guidelines.
- Strap tension can be increased to maximum strength for short periods, and then eased off slightly for long-term wear.
- It is important to monitor PIP joint extension once splinting is discontinued.¹⁵ Intermittent long-term splint wear has been shown to prevent reoccurrence.²⁰

Night Options:

- Strap tension should be reduced for comfort at night. Silver ring splints may not be suitable for nightwear, as the pressure on the joint cannot be eased.

Precautions:

- An early PIP joint flexion deformity may be caused by joint swelling, and may not mean that a Boutonnière is developing. Monitor DIP joint position and test the ORL and central slip to see if a deformity is developing. Early use of an anti-boutonniere splint, with joint inflammation, may stretch the volar plate and encourage development of a Swan Neck deformity.
- Skin breakdown
- Increased joint swelling
- Once PIP joint full extension has been achieved and splint is discontinued, joint should be monitored for loss of range and reoccurrence of deformity.¹⁵
- Do not reduce circulation by applying Coban too tightly.

- Splints limit function when flexion is needed.
- Splints are easy to lose.

Contraindications:

- Acutely inflamed PIP joint; use gutter splint and reduce tension on strap, or use Coban or Digi-sleeve.
- Poor circulation, impaired sensation, fragile skin
- Scleroderma
- Allergy to materials

Joint Protection

Avoid activities with prolonged and forceful PIP joint flexion. For example:

- Avoid tight tripod pinch when writing. A pen grip can relax the fingers.
- Avoid small handles on tools and utensils (vegetable peelers, knives, toothbrushes). Large padded handles are easier to grasp.
- Avoid holding plastic grocery bags and suitcases in a “hook” grasp, which puts pressure on the PIP joints in flexion, and encourages MCP joint hyperextension. Use shoulder straps, backpacks or adapted handles instead.^{14, 25}

Note: These recommendations are based on materials ranging from systematic reviews, published studies, expert opinion, reviews of clinical texts and the expertise of the physiotherapists and occupational therapists at the Mary Pack Arthritis Program.

REFERENCES

1. Ruby LK (editor). Hand Clinics- Rheumatoid Arthritis of the Hand and Wrist.1996;12:537-538.
2. Klinkhoff A et al. An Experiment in Reducing Interobserver Variability of the Examination for Joint Tenderness. Journal of Rheumatology. 1988;15-3:492-494.
3. Bombardier C. et al. Illustrated Guide to a Standard Examination for JointTenderness and Swelling. 1987
4. Groth G. et al. Goniometry of the Proximal and Distal Interphalangeal Joints - Part I. Journal of Hand Therapy. Jan/Mar:2001.
5. Mackin EJ, Callahan AD, Skirven TM et al (editors). Rehabilitation of the Hand and Upper Extremity. 5th ed. Mosby: 2002;125-133.
6. Smith PJ, Ross DA. The Central Slip Tenodesis Test for Early Diagnosis of Potential Boutonniere Deformities. J Hand Surg 1994;19B:88-90.
7. Hoppenfeld S. Physical Examination of the Spine and Extremities. Prentice-Hall;1976:102.

8. Melvin JL. Rheumatic Disease in the Adult and Child: Occupational Therapy and Rehabilitation. 3rd ed. Philadelphia: F.A. Davis Company:1989:347.
9. Backman C. et al. Arthritis Hand Function Test: Development of a Standardized Assessment Tool. Occupational Therapy Journal of Research. 1991;11-4:245-256.
10. Mackin EJ, Callahan AD, Skirven TM et al (editors). Rehabilitation of the Hand and Upper Extremity. 5th ed. Mosby:2002;1573 -1577.
11. Ottawa Panel Evidence-Based Clinical Practice Guidelines for Electrotherapy and Thermotherapy Interventions in the Management of Rheumatoid Arthritis in Adults. Physical Therapy 2004;84-11:1016-1043.
12. Wessel J. The effectiveness of Hand Exercises for Persons with Rheumatoid Arthritis – A Systematic Review. Journal of Hand Therapy 2004;17:74-180.
13. Wehbe M. Tendon Guiding Exercises. American J of OT 1987;41;3:164-167.
14. Melvin JL. Rheumatic Disease in the Adult and Child: Occupational Therapy and Rehabilitation. 3rd ed. Philadelphia: F.A. Davis Company:1989:427.
15. Cannon MN. Diagnosis and Treatment Manual for Physicians and Therapists. 4th ed. Hand Rehabilitation Centre of Indiana:67-69.
16. Li-Tsang CW, Hung LK, Mak AF. The Effect of Corrective Splinting on Flexion Contracture of Rheumatoid Fingers. J Hand Therapy 2002;15:185-191.
17. Arthritis College of Rheumatology – ACR Core Curriculum CD-ROM.
18. Chung KC et al. Reliability and Validity Testing of the Michigan Hand Outcome Questionnaire. Journal of Hand Surgery 1998;23A:575-587
19. Mackin EJ, Callahan AD, Skirven TM et al (editors). Rehabilitation of the Hand and Upper Extremity. 5th ed. Mosby: 2002;1748-50.
20. Melvin JL. Rheumatic Disease in the Adult and Child: Occupational Therapy and Rehabilitation. 3rd ed. Philadelphia: F.A. Davis Company:1989;287-288.
21. Cochrane Musculoskeletal group Cochrane Database of Systematic Reviews 1, 2006:
 - Robinson et al. Thermotherapy for treating rheumatoid arthritis Robinson et al.; Brousseau L et al. Transcutaneous electrical nerve stimulation for the treatment of rheumatoid arthritis in the hand; Casimiro et al. Therapeutic ultrasound for the treatment of rheumatoid arthritis; Brousseau L et al. Low-level laser (class 1,11,111) for treating rheumatoid arthritis.
22. Westby MD, Minor MA. Exercise and Physical Activity. In: Clinical Care in the Rheumatic Diseases. 3rd ed. Atlanta: Association of Rheumatology Health Professionals:2006;211-220
23. Myths and Truths of Stretching; Orthopedic Division Review Jan/Feb 2001
24. Elson RA. Rupture of the Central Slip of the Extensor Hood of the Finger - A Test for Early diagnosis. J Bone Joint Surg 1986;68B:2:229-231.
25. Biese J. Therapist's Evaluation and Conservative Management of Rheumatoid Arthritis in the Hand and Wrist. 5th Edition. Missouri: Mosby 2002;1569-1582
26. Hoens A. Evidence-Informed Practice for Range of Motion, Stretching and Prolonged Positioning. Providence Health Care - Physiotherapy Services. 2011.